

Rationale and Use of the Critical View of Safety in Laparoscopic Cholecystectomy

Steven M Strasberg, MD, FACS, L Michael Brunt, MD, FACS

The introduction of laparoscopic cholecystectomy was associated with a sharp rise in the incidence of biliary injuries.¹ Despite the advancement of laparoscopic cholecystectomy techniques, biliary injury continues to be an important problem today, although its true incidence is unknown. The most common cause of serious biliary injury is misidentification. Usually, the common bile duct is mistaken to be the cystic duct and, less commonly, an aberrant duct is misidentified as the cystic duct.² The former was referred to as the “classical injury” by Davidoff and colleagues, who described the usual pattern of evolution of the injury at laparoscopic cholecystectomy.³ In 1995, we authored an analytical review of this subject and introduced a method of identification of the cystic structures referred to as the “critical view of safety” (CVS)² (Fig. 1). (This approach to ductal identification had been described in 1992,⁴ but the term *critical view of safety* was used first in our 1995 article.) During the past 15 years, this method has been adopted increasingly by surgeons around the world for performance of laparoscopic cholecystectomy.⁵⁻⁸ When the method was initially described, it was done so with a brief description and picture, without a thorough explanation of the rationale for this approach.² The primary purpose of this short communication is to present that rationale so that surgeons can better apply CVS by understanding why the method is protective against misidentification. A second purpose is to review the current status of the use of CVS and to suggest approaches that might reduce the incidence of biliary injury through its use.

Rationale of the CVS

The CVS has 3 requirements.² First, the triangle of Calot must be cleared of fat and fibrous tissue. It does not require that the common bile duct be exposed. The second requirement is that the lowest part of the gallbladder be separated from the cystic plate, the flat fibrous surface to which the nonperitonealized side of the gallbladder is attached. The cystic plate, which is sometimes referred to as the liver bed of the

gallbladder, is part of the plate/sheath system of the liver.^{9,10} The third requirement is that 2 structures, and only 2, should be seen entering the gallbladder. Once these 3 criteria have been fulfilled, CVS has been attained (Fig. 1).

The rationale of CVS is based on a 2-step method for ductal identification that was and continues to be used in open cholecystectomy. First, by dissection in the triangle of Calot, the cystic duct and artery are putatively identified and looped with ligatures. Next, the gallbladder is completely dissected off the cystic plate, demonstrating that the 2 structures are the only structures still attached to the gallbladder (Fig. 2). Incorporation of the freeing of the gallbladder off the cystic plate so that the gallbladder is hanging from the cystic duct and artery is superior to simply demonstrating that 2 structures are entering the gallbladder because it shows that 2 and only 2 structures are attached to the gallbladder.

During our early experience with laparoscopic cholecystectomy, attempts were made to replicate this open approach laparoscopically.⁴ However, considerable difficulties were encountered. First, it was more difficult laparoscopically to take the gallbladder off the cystic plate completely without first dividing the cystic duct and artery than it was with the open technique. Another problem was the gallbladder tended to twist on the cystic structures after it was freed from its attachments to the liver, resulting in greater difficulty in clipping and dividing the cystic artery and duct. In the course of these laparoscopic attempts to mimic the open method, it was realized that the same fidelity of identification obtained by taking the gallbladder off the cystic plate completely could be achieved by clearing only the lower part of the gallbladder off the plate, leaving the upper part of the gallbladder attached. In addition, the twisting problem, which occurred when the gallbladder was detached completely, was not present when the fundus of the gallbladder remained attached to the liver. At that point, the question became what was the least amount of gallbladder that must be separated from the cystic plate to achieve the fidelity of identification attained when the whole gallbladder is removed. Logically, the amount is that which allows the surgeon to conclude that the gallbladder is being dissected off the cystic plate itself and not just being separated from attachments within the triangle of Calot (Fig. 3A). In our 1995 article,² this was demonstrated pictorially (Fig. 1), as opposed to stipulating a fixed extent of cystic plate that had to be exposed, because the area that had to

Disclosure Information: Nothing to disclose.

Received January 29, 2010; Accepted February 26, 2010.

From the Sections of Hepato-Pancreato-Biliary Surgery and Minimally Invasive Surgery, Washington University in St Louis, St Louis, MO.

Correspondence address: Steven M Strasberg, MD, Section of Hepato-Pancreato-Biliary Surgery, Department of Surgery, Washington University in St Louis, Suite 1160, Northwest Tower, 660 South Euclid Ave, Box 8109, St Louis, MO 63110. email: strasbergs@wustl.edu

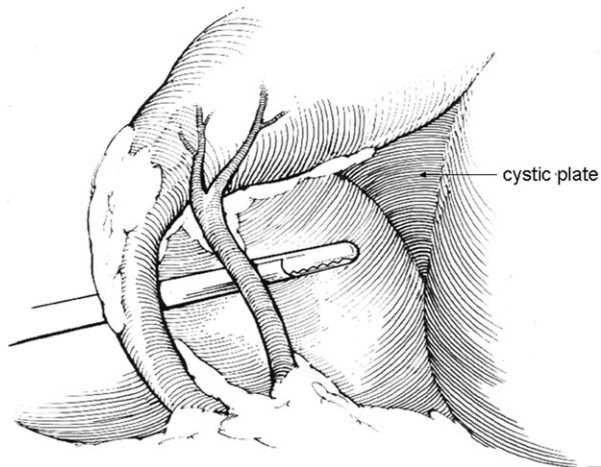


Figure 1. The critical view of safety. The triangle of Calot has been dissected free of fat and fibrous tissue, however, the common bile duct has not been displayed. The base of the gallbladder has been dissected off the cystic plate and the cystic plate can be clearly seen. Two and only 2 structures enter the gallbladder and these can be seen circumferentially.

be cleared to be sure that dissection had been carried onto the cystic plate could differ somewhat from case to case. The cystic plate, being made of fibrous tissue, usually has a dull white appearance (Fig. 3B). Occasionally, it is thin and translucent, allowing the underlying liver to be seen through it (Fig. 4A). In cases with mild inflammation and areolar dissection planes, only a centimeter or so of the cystic plate needs to be cleaned free of gallbladder attachments to ensure that dissection is actually on the fibrous plate. When there is greater inflammation that distance can be greater because fibrotic chronically inflamed tissues within the triangle of Calot can also have the same dull white color as the cystic plate (see Fig. 4B). The extent of dissection has to be that which results in the method being an adequate surrogate to dissecting the gallbladder off the liver bed entirely. Therefore, distance dissected needs to be that which makes it obvious that the only step left in the dissection—if the cystic structures were to be divided—would be removal of the remaining attachments of the gallbladder to the liver.

Although the Figure that was used to illustrate the technique clearly showed that the bottom of the gallbladder was freed from the cystic plate (Fig. 1), the rationale was not explained clearly. Consequently, surgeons might not understand why this is an essential step in the procedure, as explained here. Sometimes surgeons clear a small area of the triangle of Calot above the cystic artery as well as the area between the cystic duct and artery (Fig. 3A) and consider that this fulfills the requirements of the method. It does not. The making of 2 “windows” alone does not satisfy the requirements of CVS. To do so, enough of the gallblad-

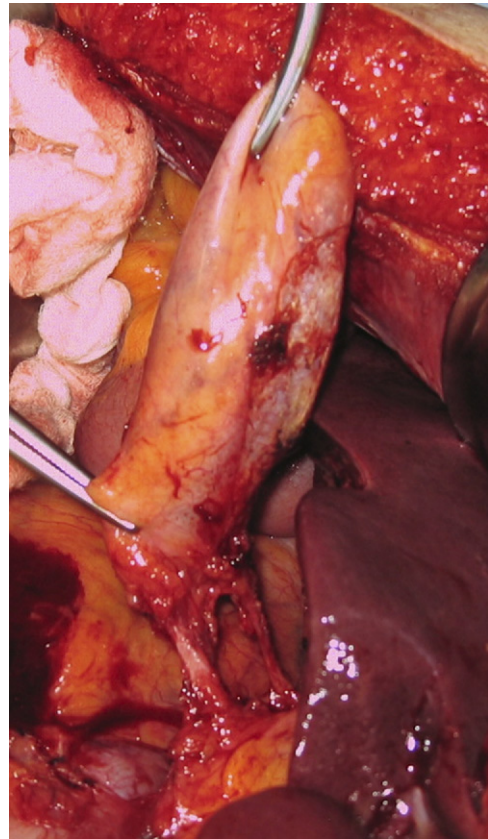


Figure 2. Identification of the cystic structures at open cholecystectomy. The gallbladder has been completely dissected off the cystic plate and 2 and only 2 structures are entering the gallbladder. The method employs putative identification of the cystic structures in the triangle of Calot before dissection of the gallbladder off the plate.

der should be taken off the cystic plate so that it is obvious that the only step left after division of the cystic structures will be removal of the rest of the gallbladder off the cystic plate (Fig. 3B). Also, although the common duct does not have to be seen, all fat and fibrous tissue must be removed from the triangle of Calot so that there is a 360-degree view around the cystic duct and artery, ie, the CVS should be apparent from both the anterior and posterior (reverse Calot) viewpoints (Fig. 4). The purpose of the grasper in the picture of the critical view is to precisely indicate that a 360-degree view is required (Fig. 1).

Use of the CVS technique

Standard procedure—mild and moderate inflammation present

The initial steps in performance of a laparoscopic cholecystectomy are similar in most methods. A pneumoperitoneum is created, ports are inserted under direct vision, and graspers are placed on the gallbladder for retraction. The next step is to clear the triangle of Calot of fat and fibrous

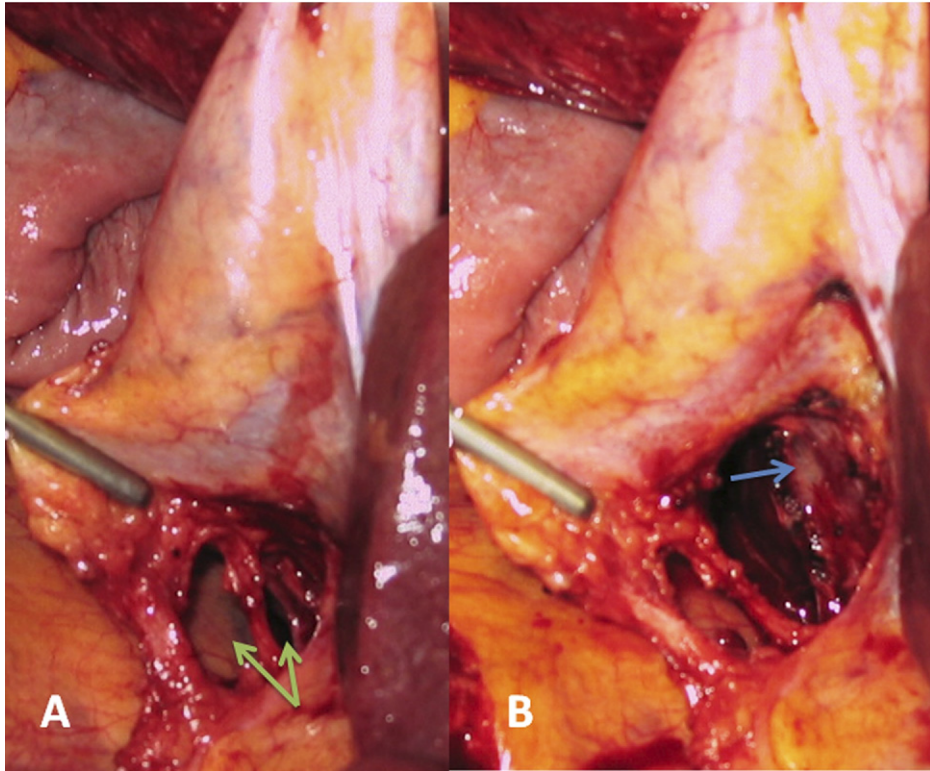


Figure 3. Difference between 2 “windows” and critical view of safety (CVS). (A) Dissection has led to the creation of 2 windows, 1 between the cystic duct and artery and 1 between the artery and the liver (arrows). This dissection does not fulfill the criteria of CVS because the cystic plate cannot be clearly identified. (B) CVS. Arrow points to whitish clearly identified cystic plate.

tissue. This can be done with a variety of techniques, which include teasing tissue away with graspers or gauze dissectors, elevating and dividing tissue with hook cautery, and spreading tissue with blunt or curved dissecting instru-

ments. The dissection is commonly performed from the front and the back of the triangle of Calot. Two points of safety for cautery are that it should be used on low power settings, typically ≤ 30 W and that any tissue to be cauter-

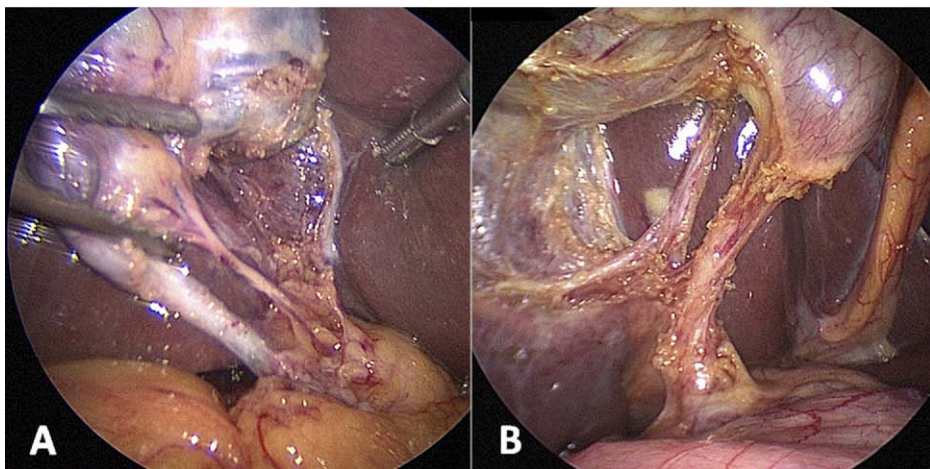


Figure 4. Different appearances of the cystic plate. (A) Critical view of safety (CVS) is seen from in front of the gallbladder as usually shown. The cystic plate is very thin. (B) CVS is seen with the gallbladder reflected to the left so that a posterior view of the triangle of Calot is shown. The cystic plate is thicker and whitish. Both views fulfill criteria for CVS.

ized should be elevated off surrounding tissue so that there is no unintentional arcing injury to surrounding structures. Cautery should be applied in short bursts of 2 to 3 seconds or less to minimize thermal spread to surrounding structures. Also, it is important that only small pieces of tissue be divided at one time because important biliary structures can be quite small in diameter. Using these approaches, it is usually not difficult to clear the triangle of Calot of fat and fibrous tissue and take the gallbladder off the bottom of the cystic plate when mild or moderate inflammation is present. Once this is done, there will be 2 and only 2 structures attached to the gallbladder and they can be visualized circumferentially. At this point, the CVS has been achieved and the cystic structures can be divided. If any doubt exists, as can occur when inflammation is severe, then more of the gallbladder should be taken off the cystic plate, including right up to the fundus, if necessary. When dividing the cystic structures, it is our practice to divide the artery first because it is usually shorter than the cystic duct and doing so permits a longer length of cystic duct to appear. This also facilitates insertion of a catheter in the cystic duct for performing intraoperative cholangiography. Of course, both structures must be clipped and divided in a manner that avoids tenting injury.

Most of the instructions in the literature about the safe removal of the gallbladder laparoscopically, such as those in the preceding paragraph, are related to how the dissection is done. The CVS is not a dissection technique, but rather a technique of identification. As such, it is related to methods of safe identification in other aspects of life. For instance, state hunting regulations stipulate that hunters must see the head and torso of an animal before firing a shot, as opposed to shooting after seeing legs only. Pilots identify runways as opposed to taxiways by blinking approach lights, white runway lights, and radio beacons. These safeguards are about identification as opposed to the mechanics of hunting or flying. Similarly, it is important for the surgeon to separate dissection and identification in his or her mind. Dissection is temporally linear but identification is temporally static. Dissection reveals the CVS, but affirmation that the CVS has been achieved takes place in a moment of time when no dissection is going on. Affirmation of the CVS should take place at a pause in the operation and should be treated like a second timeout. The critical view should be demonstrated and ideally the surgeon and physician assistant, if present, should agree that it is achieved, just as a pilot and copilot agree on critical points of identification when flying an airplane. Using these approaches, CVS is usually achievable in standard laparoscopic cholecystectomy, in single-incision laparoscopic

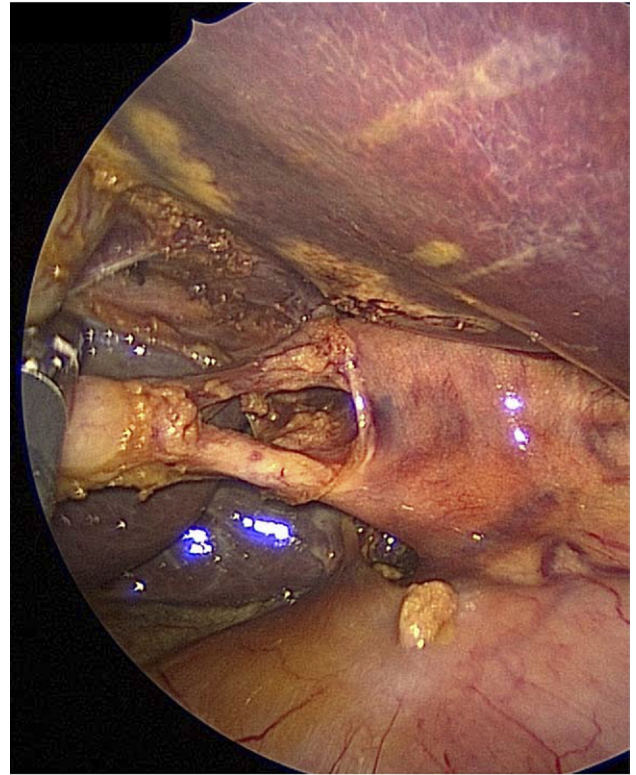


Figure 5. Critical view of safety (CVS) obtained a single-incision laparoscopic cholecystectomy. Although the view is rotated counter-clockwise from usual, all the criteria of CVS are present.

cholecystectomy¹¹ (Fig. 5), and in natural orifice transluminal endoscopic cholecystectomy.⁸

CVS in severe inflammation

The preceding was a description of use of the critical view in the straightforward cholecystectomy in which there is minimal or moderate inflammation and even when aberrant ducts are present. In the latter case, ducts can be found to cross the triangle of Calot and even unite with the cystic duct, but they will not enter the gallbladder and their presence does not interfere with attaining CVS. However, circumstances can be very different when there is severe inflammation. (Although there are rare descriptions of right hepatic ducts directly entering the gallbladder, this is probably not a result of an anomaly of this type but rather an effacement of the cystic duct by a large stone [as in Mirizzi syndrome] under conditions in which the cystic duct terminates in a low-lying right hepatic duct. In all such cases, there will be severe chronic inflammation. Developmentally, it is extremely unlikely that the right hepatic ductal system could bud off the side of the gallbladder. The preceding does not refer to the accessory ducts of Luschka, which are minute nonessential ducts that pass through the

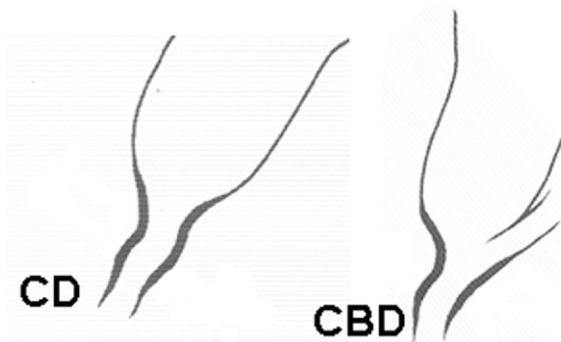
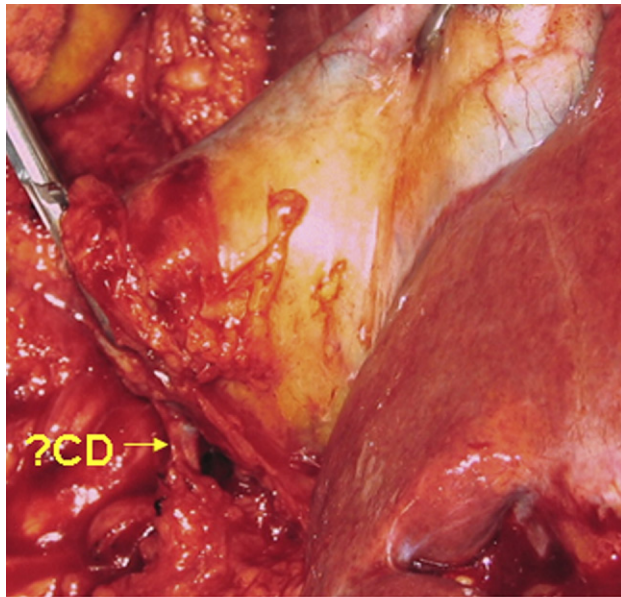


Figure 6. The infundibular view technique of ductal identification. The putative cystic duct (CD) been dissected circumferentially to the edge of the gallbladder, obtaining the funnel-shaped view shown in the lower left diagram. Unfortunately, sometimes the same appearance can be given when the common bile duct (CBD) is dissected, especially when severe inflammation is present and the common hepatic duct adheres to the side of the gallbladder and the cystic duct is hidden (lower right diagram).

cystic plate to communicate between the gallbladder lumen and intrahepatic ducts.)

Surgeons are more likely to dissect the common bile duct circumferentially and believe it is the cystic duct in the presence of severe acute and chronic inflammation.¹² This occurs because certain factors present under these circumstances tend to hide the cystic duct and fuse the common hepatic duct to the side of the gallbladder.^{12,13} It is clear from operative notes that such circumstances can result in a compelling deception that the common duct is the cystic duct. The result in many cases has been bile duct injury.¹² If the surgeon is using a method, such as the infundibular view technique (Fig. 6), and has come around the common bile duct thinking that it is the cystic duct, a 360-degree

view of a funnel-shaped structure resembling the union of cystic duct and gallbladder can be obtained¹² (Fig. 6). As this funnel shape is the requirement for identification by this method (infundibulum = funnel), the common bile duct will often be clipped and divided.¹² The common bile duct can be similarly dissected in error when using the critical view technique, but it will not be divided at this point because the other conditions for the CVS have not been met. The cystic artery has not been identified, the triangle of Calot has not been completely cleared, and the base of the cystic plate has not been displayed. Under the same inflammatory conditions that lead to biliary injury in the infundibular view technique, the surgeon using the CVS will have difficulty proceeding after isolation of the common bile duct. This is actually desirable and should suggest that there is a problem. It is important that the surgeon recognizes when this step in the operation becomes very difficult because it suggests there is a problem and additional attempts to attain CVS laparoscopically should be halted. Options include intraoperative cholangiography, conversion to open cholecystectomy, or soliciting the help of a colleague. Stated otherwise, the critical view method is superior to the infundibular technique under conditions of severe inflammation because it is more rigorous. The patient is protected precisely because the surgeon cannot usually achieve a misleading view. However, although CVS will usually protect against making incorrect identification, it will not protect against direct injury to structures by persistent dissection in the face of highly adverse local conditions.

Photo documentation of CVS

Photo documentation of CVS has been recommended by Heistermann and colleagues⁶ and by the Dutch Society of Surgery,¹⁴ although the optimal method for documentation has not been systematically studied. This recommendation might gain support especially as newer methods of cholecystectomy, such as single-incision cholecystectomy, natural orifice transluminal endoscopic cholecystectomy,⁸ and robotic cholecystectomy are introduced. Photo documentation might be achieved by still photos or by short video. Still photographs have the advantage of being readily printable and could be added to the patient's chart.¹⁵ The photographs are also immediately available for review and are easier to store than video. However, in evaluating whether CVS has been achieved, surgeons frequently move the lower end of the gallbladder to scan the triangle of Calot from in front and from behind. As a result, a short video of 20 to 30 seconds, as shown in the video clip of CVS (available online) can more accurately replicate what the surgeon is viewing for documentation purposes. Anecdotal experience from our group suggests that for single-

incision laparoscopic cholecystectomy, a video segment can be superior to still photographs because of the ability to examine both sides of the hepatocystic triangle.

Evidence that CVS prevents biliary injuries

Yegiyants and colleagues reported on 3,042 patients who had laparoscopic cholecystectomy using CVS for identification in the period 2002–2006.⁷ The study was limited because data were obtained from an administrative database and CVS was not used in all laparoscopic cholecystectomies. One bile duct injury occurred in an 80-year-old patient with severe inflammation. The injury occurred during dissection before the CVS was achieved, ie, none of 3,042 patients having laparoscopic cholecystectomy had an injury because of misidentification. The expected rate of injury was between 2 and 4 per 1,000 cholecystectomies and most would be expected to result from misidentification. The actual rate of injury was much lower than the expected rate.⁷

Avgerinos and colleagues reported on 1,046 patients having laparoscopic cholecystectomy in a single institution from 2002–2007.⁵ In 998 cases CVS was used. The conversion rate was 2.7%. There were 5 bile leaks, which resolved spontaneously. No major bile duct injuries occurred.⁵

Heistermann and colleagues reported on 100 patients who had laparoscopic cholecystectomy using CVS.⁶ The purpose of the study was to determine how often it was possible to attain CVS and demonstrate it with photo documentation. Despite a high incidence of acute cholecystitis and prior abdominal surgery, 97 of 100 cholecystectomies were completed laparoscopically after achieving photo documentation of CVS. There was 1 postoperative cystic duct stump leak.⁶

Wauben and colleagues reported on use of ductal identification techniques in The Netherlands, including CVS.¹⁶ In this survey, it was found that Dutch surgeons used a variety of techniques for ductal identification, but few surgeons used CVS. Subsequently, the Dutch Society of Surgery established a commission to study the problem of biliary injury in that country. The commission developed best practice guidelines for performing cholecystectomy and adopted CVS as the standard method of performing ductal identification.¹⁴ Photo documentation of CVS before division of the cystic duct was recommended in these guidelines.¹⁴ At this time, all Dutch surgeons performing laparoscopic cholecystectomy are expected to follow the guidelines. As yet, there is no published information regarding whether this policy has been successfully implemented or whether it has affected the incidence of bile duct injury in The Netherlands.

In summary, there is no Level I evidence that CVS reduces bile duct injury. To prove this claim would require a

randomized trial. The difficulty in performing such a trial can be illustrated as follows: even if there was a 4-fold increase in the incidence of biliary injury from 0.1% to 0.4% as a result of introduction of laparoscopic cholecystectomy, it would be difficult to detect because a randomized trial would require 4,500 patients per arm to detect that difference at a 95% confidence level. The logistics and cost of performing a surgical trial of this magnitude are overwhelming. Probably the best that can be achieved is the all or none Level I type of evidence, in which it is shown that biliary injuries resulting from misidentification do not occur when a particular technique is used; from a practical perspective, that would be sufficient. The case series of Yegiyants and colleagues⁷ and Avgerinos and colleagues⁵ approach that standard. The results of the Dutch best practices initiative will be of great interest and might provide additional support for CVS if the policy is implemented successfully and if it results in a reduction in biliary injuries in The Netherlands.

Author Contributions

Study conception and design: Strasberg

Acquisition of data: Strasberg, Brunt

Analysis and interpretation of data: Strasberg, Brunt

Drafting of manuscript: Strasberg

Critical revision: Strasberg, Brunt

REFERENCES

1. A prospective analysis of 1518 laparoscopic cholecystectomies. The Southern Surgeons Club. *N Engl J Med* 1991;324:1073–1078.
2. Strasberg SM, Hertl M, Soper NJ. An analysis of the problem of biliary injury during laparoscopic cholecystectomy [see comments]. *J Am Coll Surg* 1995;180:101–125.
3. Davidoff AM, Pappas TN, Murray EA, et al. Mechanisms of major biliary injury during laparoscopic cholecystectomy. *Ann Surg* 1992;215:196–202.
4. Strasberg SM, Sanabria JR, Clavien PA. Complications of laparoscopic cholecystectomy. *Can J Surg* 1992;35:275–280.
5. Avgerinos C, Kelgiorgi D, Touloumis Z, et al. One thousand laparoscopic cholecystectomies in a single surgical unit using the “critical view of safety” technique. *J Gastrointest Surg* 2009;13:498–503.
6. Heistermann HP, Tobusch A, Palmes D. [Prevention of bile duct injuries after laparoscopic cholecystectomy. “The critical view of safety”]. *Zentralblatt für Chirurgie* 2006;131:460–465.
7. Yegiyants S, Collins JC, Yegiyants S, Collins JC. Operative strategy can reduce the incidence of major bile duct injury in laparoscopic cholecystectomy. *Am Surg* 2008;74:985–957.
8. Auyang ED, Hungness ES, Vaziri K, et al. Natural orifice transluminal endoscopic surgery (NOTES): dissection for the critical view of safety during transcolonic cholecystectomy. *Surg Endosc* 2009;23:1117–1118.
9. Couinaud C. The vasculo-biliary sheaths. In: Couinaud C, ed. *Surgical anatomy of the liver revisited*. Paris; 1989:29–39.

10. Strasberg SM, Linehan DC, Hawkins WG. Isolation of right main and right sectional portal pedicles for liver resection without hepatotomy or inflow occlusion. *J Am Coll Surg* 2008;206:390–396.
11. Hodgett SE, Matthews BD, Strasberg SM, Brunt LM. Single incision laparoscopic cholecystectomy (SILC): initial experience with critical view dissection and routine intraoperative cholangiography. *Surg Endosc* 2009;23:S332.
12. Strasberg SM, Eagon CJ, Drebin JA. The “hidden cystic duct” syndrome and the infundibular technique of laparoscopic cholecystectomy—the danger of the false infundibulum. *J Am Coll Surg* 2000;191:661–667.
13. Strasberg SM, Strasberg SM. Error traps and vasculo-biliary injury in laparoscopic and open cholecystectomy. *J Hepato-Biliary-Pancreatic Surg* 2008;15:284–292.
14. Gallstone disease (Galsteenziekte) 2007. Dutch Society of Surgery. Available at: <http://nvvh.artsennet.nl/richtlijnen/Bestaanderichtlijnen.htm> [in Dutch]. Accessed January 27, 2010.
15. Plasier PW, Pauwels MMA, Lange JF. Quality control in laparoscopic cholecystectomy: operation notes, video or photo print. *HPB (Oxford)* 2001;3:197–199.
16. Wauben LS, Goossens RH, van Eijk DJ, et al. Evaluation of protocol uniformity concerning laparoscopic cholecystectomy in the Netherlands. *World J Surg* 2008;32:613–620.